

## TOXIC EFFECTS ON FETAL KIDNEY INDUCED BY PRENATAL ADMINISTRATION OF ZIDOVUDINE IN SWISS ALBINO MICE

Amit Nayak, Mandavi Singh and Anand Mishra\*

Department of Anatomy, Institute of Medical Sciences, Banaras Hindu University, Varanasi-221005

### ABSTRACT

**Introduction** – Zidovudine is an NRTI approved by FDA for treatment of HIV. It is used as one of the component of highly active antiretroviral therapy (HAART) to prevent maternal to child transmission (MTCT). But its effect on fetal kidney is yet to be ascertained.

**Materials and methods** – Pregnant albino mice was given zidovudine in the dose of 50mg/kg, 100mg/kg, 50mg/kg by oral gavage from 6th - 15th day of gestation and control mice was fed distilled water during the same period. On 17th day maternal blood was collected for renal function test by retro orbital vein puncture. On 18th day the mice was sacrificed and fetuses were taken out. The kidney of foetuses were dissected, fixed with formalin, processed and stained with H&E for micromorphological study.

**Results**- The treated fetal kidney shows decreased glomerular tufts hyalinised and reduced tubules and ultimately loss of architecture of renal parenchyme in a dose related manner. The serum urea was increased and hyponatremis, hypokalemia, hypochloridemia was observed in dams depicting toxic effect of this drug on kidney of the mice.

**Conclusion**- Zidovudine causes nephrotoxicity in both mother and fetus if given prenatally to mice and so should be used with care during pregnancy.

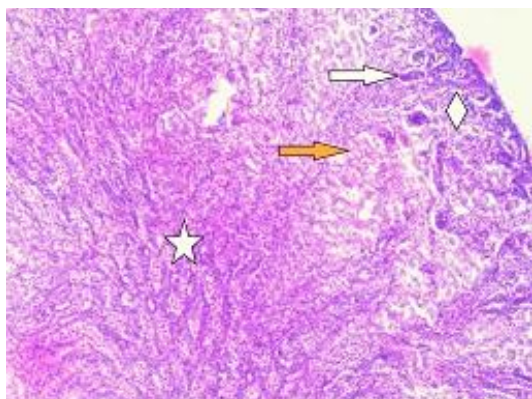
The acquired immune deficiency syndrome (AIDS) is a potentially fatal transmissible disease caused by Human Immunodeficiency Virus (HIV). Widely recognised as the most significant new infectious disease to emerge during the twentieth century HIV-1 infection has already claimed 20 million lives and currently over 34 million people carry the infection<sup>1</sup>

Transmission of HIV from infected mother to their infants can occur through various ways. In a minority of cases, the transmission appears to occur in utero by transmission through placenta. More commonly, transmission occurs at the time of birth. Remarkably, over two-thirds of the times, infants born to infected mothers remain HIV-1 negative. Lastly transmission can also occur through breast feeding.<sup>1</sup>

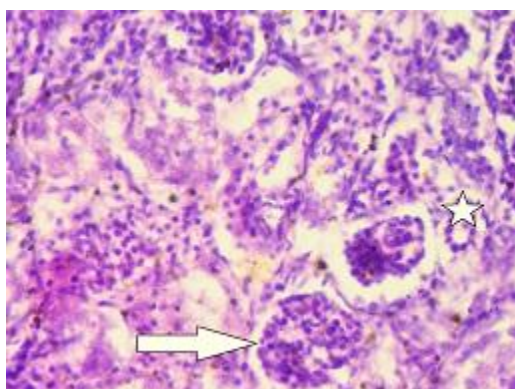
Zidovudine belongs to a class of antiretroviral drug called as Nucleoside Reverse Transcriptase Inhibitors (NRTIs). Zidovudine is a prodrug and must be phosphorylated in lymphocytes in order to exert its antiviral action. Zidovudine is first phosphorylated to their monophosphate by thymidine kinase, followed by a second rate-limiting phosphorylation step which is carried out by thymidylate kinase. The diphosphate product is further phosphorylated by the enzyme diphosphate kinase to yield deoxynucleoside-5'-triphosphate, the active form against HIV replication. Currently, administration of Zidovudine and Lamivudine (3TC), often in combination with additional antiretroviral agents, constitutes standard clinical practice for prevention of mother to child transmission (PMTCT)<sup>2</sup>. The US Food and Drug Administration (FDA) continue to place ZDV therapy in pregnancy in risk and it has been classified as a class "C" drug which means that studies in human are inconclusive and thus should be used only when benefits outweigh the risk in pregnancy.<sup>3</sup>

Studies established that zidovudine exposure during first half of murine pregnancy results not only in fewer fetuses per mouse but in significantly diminished crown-to-rump lengths among the fetuses survived. They suggested that growth retardation may have resulted from depressed cell division or from fetal hepatic and bone marrow cell toxicity.<sup>4</sup>

\*Corresponding Author :  
dranand5@rediffmail.com



**Figure- 1: control kidney H&E stained showing well defined cortex with glomerulus and collecting ducts. Well appreciable medulla showing proximal convoluted tubule & distal convoluted tubule is also visible.**

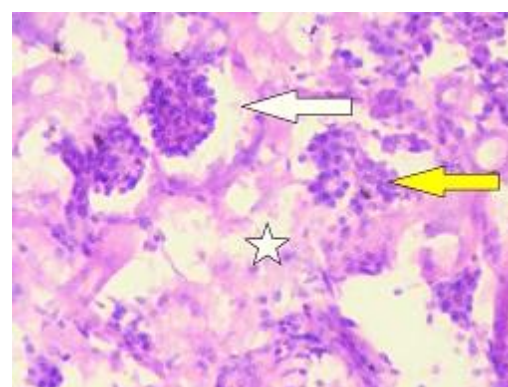
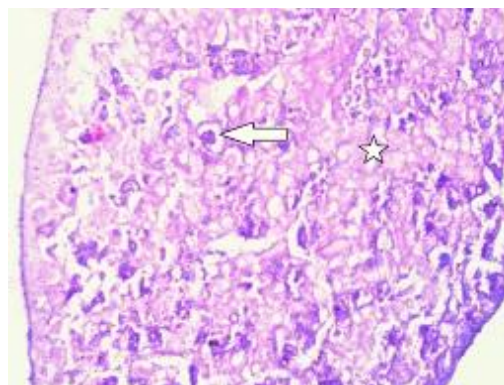


**Figure-2: control kidney H&E stained showing cortical part of kidney, glomerulus (→) and collecting ducts (\*)**

It was observed birth defects in human beings including diaphragmatic hernia, cardiac anomalies, central nervous system defects, bilateral femoral hypoplasia, cleft palate, extra digits, blue sclera and growth retardation when exposed to long term zidovudine prophylaxis<sup>5</sup>. However the effect of prenatal administration of zidovudine on fetal kidney has not yet been reported thus substantiating the utility of this study.

## MATERIALS AND METHODS

Prior approval of Institutional Ethical Committee was taken before the start of the study. Female swiss albino mice were taken for the present study and were mated with male mice in the ratio of 2:1. Presence of vaginal plug was taken as day zero of gestation (GD0). Pregnant female mice were divided into 4 groups. Group 1(Control) were given distilled water by gavage. Group 2, 3 and 4 were given Zidovudine in the doses of 50mg/kg, 100mg/kg and 150mg/kg respectively from day 6-15 of gestation by gavage. The



**Figure- 5, 6: group-2 H&E stained kidney showing degenerated glomerulus (→) , hyalinized tubules(\*) , dilated urinary space (→).**

pregnant mice were sacrificed on day 18<sup>th</sup> by cervical dislocation and the foetuses were extracted by performing uterotomy. Kidneys of foetuses were dissected out and formalin fixed for one week after which they were processed for section cutting at 6  $\mu$  and histological staining with hematoxylin and eosin.

Female dams before sacrificing were subjected to retro orbital sinus puncture and 1 ml of blood was obtained which was utilised for determining renal functional parameters of the mother.

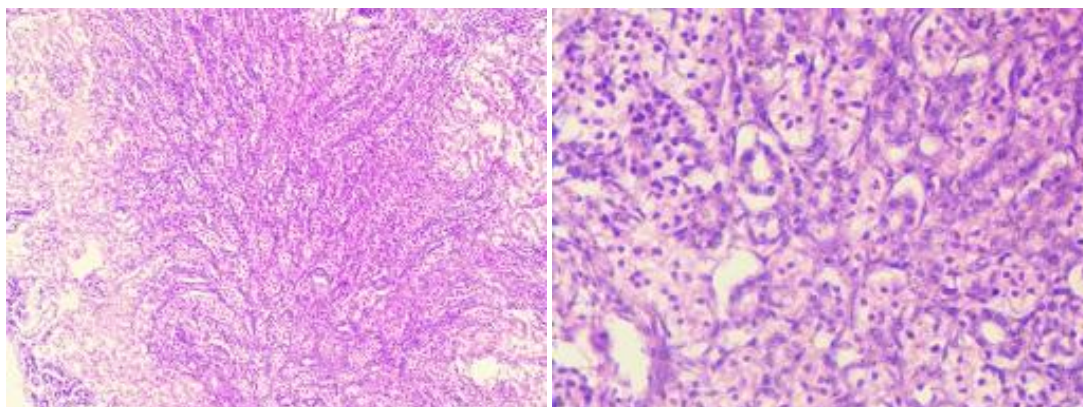
## RESULTS

### a. Control

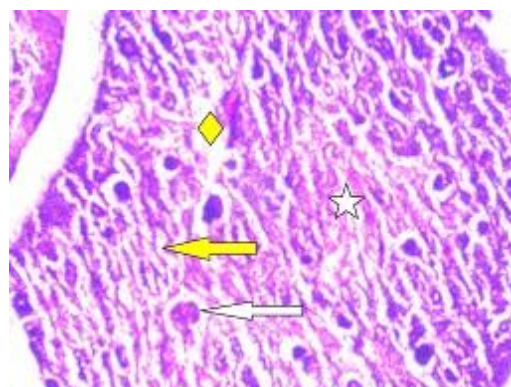
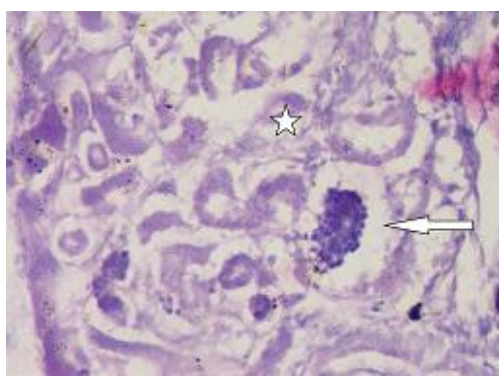
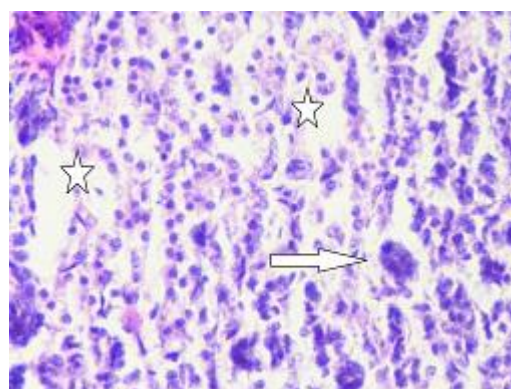
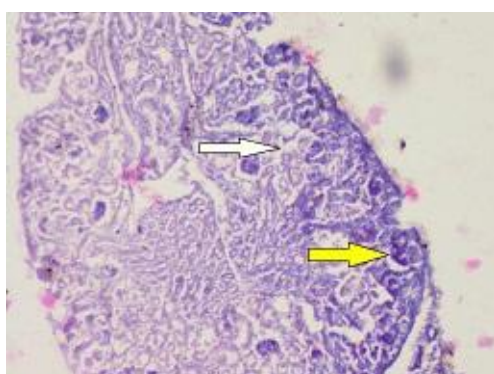
Control kidney shows well defined cortex with glomerulus and collecting ducts. Appreciable medulla shows proximal convoluted tubule & distal convoluted tubule which are remarkable in appearance.( Fig 1-4)

### b. Low dose (50mg/kg)

In the low dose treated group there is reduced density of glomerular capillaries. The mesangial cell in the glomerulus is also decreased. The periglomerular space is enlarged.



**Figure-3, 4: Control H&E stained medullary portion of the kidney depicting appreciable proximal convoluted tubule and distal convoluted tubule.**



**Figure 7, 8: group-3 H&E stained kidney showing low density of glomerulus, dilated urinary space (→) and hyalinized tubules (\*)**

**Figure 9, 10: group-4 H&E stained showing hyalinized glomerulus (→), degenerated tubules (\*) and empty lacunar spaces (◇).**

The tubules both proximal convoluted tubule (PCT) and distal convoluted tubule (DCT) are degenerated and there is fibrin deposition in the intertubular space.

Also there is inflammatory response in the form of lymphocytic infiltration in the renal parenchyma. (Fig 5, 6)

**a. Medium dose (100mg/kg)**

In the 100mg/kgbw treated group there is marked reduction in glomerular tufts and heavy

losses of tubules. Lot of cell debris of the degenerated tubules is seen in the form of karyolysis and karyorrhexis and empty lacunar spaces are seen in the renal parenchyma due to degeneration and hyalinization of tubules. (Fig7,8)

**b. High dose (150mg/kg)**

There is complete loss of cyto-architecture of renal parenchyma with negligible glomerular tufts and tubules seen. The whole parenchyma is filled with degenerated cells and hemorrhagic spots and

hyalinization denoting acute renal injury. (Fig 9, 10)

**Renal function test**

There is rise in blood urea, hyponatremia, hypokalemia and hypochloridemia in maternal

It was observed that zidovudine causes raised cholesterol level and hypertriglyceridemia which has a propensity to get deposited in the renal tubules leading to tubular degeneration.<sup>8</sup> Also the mitochondrial toxicity induced hyperlactetemia and rhabdomyolysis may induce acute

**Table 1 : COMPARATIVE VALUES OF RENAL FUNCTION TEST OF DAMS**

RENAL FUNCTION TEST	Conditions				F (3,16)
	Control Mean (SD)	Group2 Mean (SD)	Group 3 Mean (SD)	Group 4 Mean (SD)	
Blood Urea(mmol/l)	20.40 (0.55) <sup>A</sup>	48.60 (1.14) <sup>B</sup>	41.30 (0.37) <sup>C</sup>	43.08 (0.24) <sup>D</sup>	<b>1705.14***</b>
Serum Creatinine(µmol/l)	0.66 (0.09) <sup>A</sup>	0.23 (0.01) <sup>AB</sup>	0.18 (0.01) <sup>B</sup>	0.12 (0.01) <sup>C</sup>	<b>145.04***</b>
Serum Sodium(mmol/l)	149.40 (1.14) <sup>A</sup>	111.38 (0.47) <sup>BBB</sup>	111.94 (1.05) <sup>BBB</sup>	110.76 (0.67) <sup>BBB</sup>	<b>2359.80***</b>
Serum Potassium(mmol/l)	6.22 (0.08) <sup>A</sup>	24.28 (0.24) <sup>B</sup>	21.54 (0.28) <sup>C</sup>	25.29 (0.28) <sup>D</sup>	<b>7163.60***</b>
Serum Chloride(mmol/l)	110.20 (0.84) <sup>A</sup>	121.44 (0.31) <sup>CC</sup>	120.26 (0.74) <sup>B</sup>	122.00 (0.48) <sup>CC</sup>	<b>390.41***</b>

dams exposed to zidovudine suggesting deranged renal functional parameters. All these changes were statistically significant. (Table1)

**DISCUSSION**

In mammalian embryo the entire gestational period is divided into two parts, embryonic period and fetal period. The embryonic period is further subdivided into pre-organogenesis period and organogenesis period. The pre-organogenesis period coincides with first two weeks of embryonic life and any toxic insult at this stage might lead to the death of the conceptus. The organogenesis period corresponds to third to eighth week of intra-uterine life. This period is susceptible to any injury leading to congenital malformation or even death depending upon the intensity of insult. So this stage is also known as “period of insult”.<sup>6</sup>

The critical period of zidovudine toxicity in murine embryos is between ovulation and implantation period and suggested that it directly suppresses cell division in the pre implantation conceptus. It was also observed that exposure to zidovudine at any time before blastocyst formation results in immediate inhibition of cleavage and causes cell degeneration. Inhibition of cleavage in a developing pre-blastocyst by zidovudine may prohibit development beyond blastocyst stage as a critical number of cells in inner-cell mass is required for further development.<sup>7</sup>

nephrotoxicity<sup>9</sup>. It has also been reported that zidovudine can lead to Fanconi syndrome and nephrogenic diabetes insipidus<sup>10, 11</sup>. On micromorphological observation of fetal kidney we observed reduction of glomerular tufts, loss of tubules, presence of cellular debris and ultimately loss of cyto-architecture of renal parenchyma, which was directly related to severity of the dose. Thus it is hypothesised that hypertriglyceridemia, hyperlactetemia and rhabdomyolysis may cause substantial pathogenic effects on renal parenchyma of fetal mice. This hypothesis is also augmented by the fact that we observed increased blood urea, hypokalemia and hyponatremia depicting substantial decrease in glomerular filtration rate and renal toxicity caused by zidovudine in pregnant dams.

Thus zidovudine should be used with care in pregnant ladies as it shows considerable toxic changes in fetal mice kidney.

**REFERENCES**

- Centers for Disease Control (CDC) and Prevention. Public Health Services Task Forces. Recommendations for use of antiretroviral drugs in pregnant HIV-1 infected women for maternal health and intervention to reduce perinatal HIV-1 transmission in the United States. Nov.26, 2003

2. Katzung BG, Masters SB, Trevor AJ. *Basic & clinical pharmacology* (McGraw Hill publishers, New York) 11<sup>th</sup> edition 427
3. Goodman and Gilman's. *The pharmacological basis of therapeutics*, 11<sup>th</sup> edition (McGraw-Hill, New York) 2006 1357
4. Gogu, S., Beckman, B, Agrawal, K. Amelioration of Zidovudine-Induced Fetal Toxicity in Pregnant Mice. *Antimicrobial Agents And Chemotherapy* 36(1992) 2370
5. Kumar RM, Hughes PF, Khurana A. Zidovudine use in pregnancy: A report on 104 cases and the occurrence of birth defects. *J Acquir Immune Defic Syndr* 7(1994), 1034
6. Moore KL, Persaud TVN. *The developing human*. 8<sup>th</sup> ed. Saunders 2009:226
7. Toltzis P, Mourton T, Magnuson T. Effect of zidovudine on preimplantation murine embryos. *Antimicrob Agents Chemother* 37 (1993) 1610
8. Hassane I, Marianne H, Perazella M. The nephrotoxic effects of HAART. *Nat. Rev. Nephrol.* 5(2003) 563
9. Chariot P, Drogou I, Lacroix-Szmania I. Zidovudine induced mitochondrial disorder with massive liver steatosis, myopathy, lactic acidosis and mitochondrial depletion. *J Hepatol* 30 (1999) 156
10. Calmy A, Hirschel B, Cooper DA. Clinical update: adverse effects of antiretroviral therapy. *www.thelancet.com* 370(2007)12
11. Mobarak YM. The in vivo and in vitro developmental toxicity and teratogenicity of the anti AIDS drugs. *Trends Appl Sci Res* 6 (2011) 208