



## HEAD GEAR EFFECT USING MINI-IMPLANT (DISTALIZATION AND INTRUSION) – A CASE REPORT

Mohammadi Begum<sup>1\*</sup>, Arjun Karra<sup>2</sup>

<sup>1</sup>DRs. Sudha and Nageswara Rao Siddhartha Institute of Dental Sciences, Gunnavaram, Vijayawada, Krishna District, Andhra Pradesh, India

<sup>2</sup>Malla Reddy Institute of Dental Sciences, Suraram, Jeedimetla, Hyderabad, Telangana State, India

### ABSTRACT

The use of implants has made a major change in orthodontic treatment mechanics. They have replaced conventional unaesthetic and compliance dependent extraoral appliances with well accepted intraoral mechanics. Implants can be used in molar and canine distalization, intrusion and in extraoral force applications. The present case report describes the use of mini-implants in a young adult patient with bialveolar protrusion, Class II molar and canine relationship, excess incisor exposure, protruded lips and gummy smile. Using mini-implants in the buccal sulcus on both sides the whole maxillary dentition was distalized and intruded to achieve Class I molar and canine relationship along with decrease in the gumminess of the smile which has provided the best possible results for this case. Overall, mini-implant can provide anchorage to produce a good facial profile even without additional premolar extraction in cases of dental Class II bialveolar protrusion.

**Key words:** Mini implants, Distalization, Teeth movement, Gummy smile.

### INTRODUCTION

The temporary anchorage devices (TADs) are successfully used as compliance independent anchorage devices in orthodontics to prevent many of the shortcomings of traditional anchorage methods<sup>1</sup>. Removable miniscrews are available in a range of body lengths and diameter, and are mainly made of pure titanium, titanium alloy, and stainless steel (SS)<sup>2</sup>. Literature in this regard has reported a great number of clinical studies suggesting that TADs may provide stable anchorage during the orthodontic treatment without requiring patient cooperation<sup>3</sup>.

Treatment of Class II cases sometimes requires distal movement of maxillary molars in order to achieve Class I molar and canine relationship. The non-extraction treatment of Class II requires posterior movement of the maxillary dentition, anterior movement of the mandibular dentition, or a combination of both. Many devices have been developed and used to distalize the maxillary molars and show positive clinical results. However, patient cooperation is a serious problem; orthodontic mechanics requiring minimal patient cooperation are desirable.<sup>4,5</sup> Intraoral appliances for maxillary molar distalization, such as the pendulum, push coils, magnets, superelastic nickel-titanium wires, the distal jet, and the molar slider, do not require extensive cooperation from patients.<sup>6-9</sup> These techniques effectively distalize both the first and second molars. However if the maxillary molars are not distalized bodily and adequate anchorage is not established to move the canines and premolars distally, anchorage will be lost very easily,<sup>10</sup> stationary anterior anchorage is required in such circumstances. Therefore additional aids are necessary to minimize the reciprocal forces.<sup>11</sup>

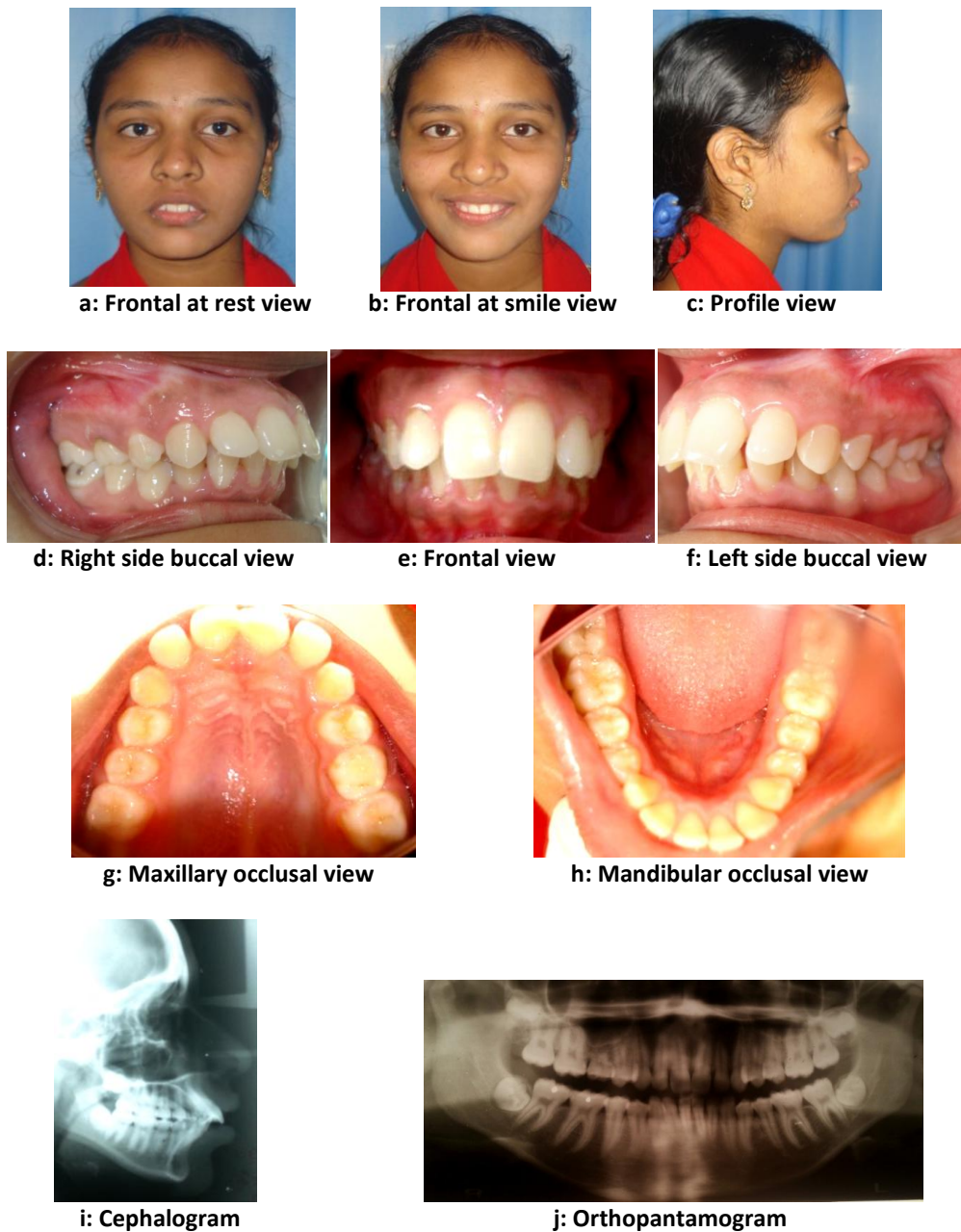
Absolute skeletal anchorage, available 24 hours a day, offers an alternative method for molar distalization. The use of osseointegrated implants<sup>12</sup>, miniplates,<sup>13</sup> miniscrews<sup>14,15</sup> and microimplants<sup>16,17</sup> as anchorage has made distalization of the posterior teeth without anchorage loss a more realistic respect.

The following case report discusses the absolute indication of using mini-implants (MI) to create an intrusion and distalization effect on the maxillary dentition to resolve the malocclusion.

**Corresponding Author:**

**Email: [sabiakareem127@gmail.com](mailto:sabiakareem127@gmail.com)**

**Figure 1(a-j): Pre treatment extraoral and intraoral photographs and radiographs**



**CASE REPORT**

A 17years old girl presented with the chief complaint of excess INCISOR exposure at rest position showing severe upper anterior teeth proclination along with gummy smile. Facially she exhibited convex profile (Fig1) with marked protrusion of the lips, mentalis muscle strain and lip incompetence but good vertical balance of facial proportions (middle and lower thirds). Intrabuccally she had Class II molar and canine relation with retained E (second deciduous molar) on right side in the upper arch. She had an 8mm deep overbite with an overjet of 10mm. There was 0.5mm crowding in the lower arch and 3mm

spacing in the upper arch. Dental asymmetry was present with a slight deviation of the maxillary dental midline to the left and of the mandibular dental midline to the right of the facial midline with no skeletal midline deviation observed. (Fig1).

The panoramic view (Fig1) shows no decayed teeth except the presence of E on the right side in the upper arch with missing second premolar tooth. The lateral cephalogram (Fig 1) and its tracing showed dental Class II bialveolar protrusion, but mild skeletal Class II pattern. The skeletal pattern was normodivergent as evidenced by the FMA (Frankfort mandibular plane angle) of

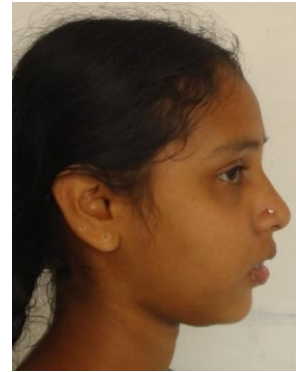Figure 2(a-h): Mid-treatment extraoral and intraoral photographs



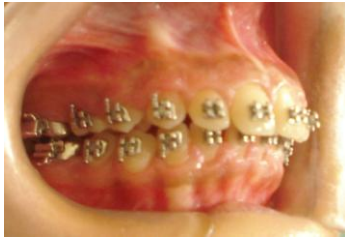a: Frontal at rest view



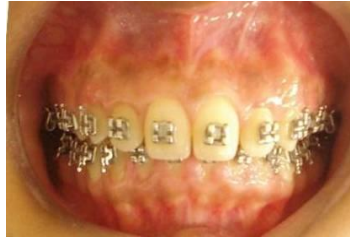b: Frontal at smile view



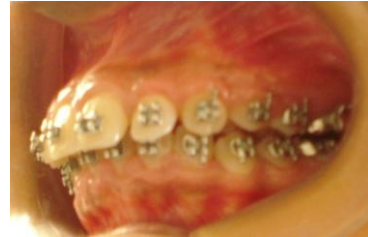c: Smile view



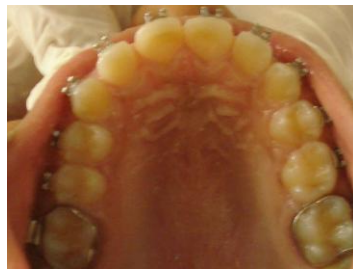d: Right side buccal view



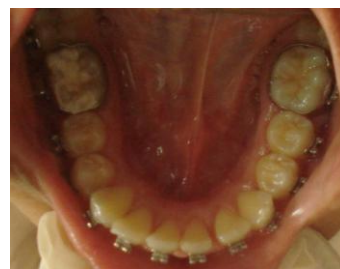e: Frontal view



f: Left side buccal view

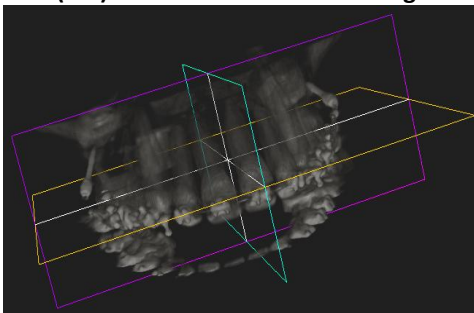


h: Maxillary occlusal view

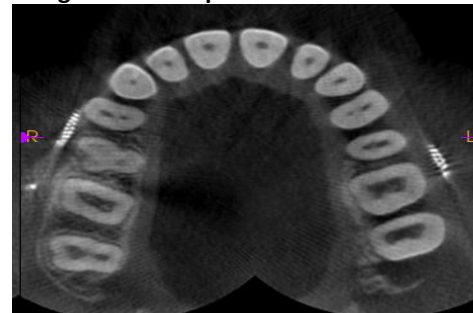

i: Mandibular occlusal view

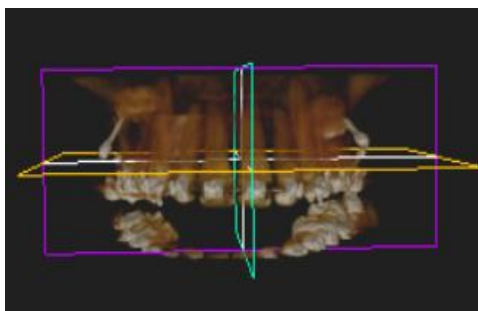
Figure 3(a-d): Mid-treatment CBCT images after placing the mini-implants



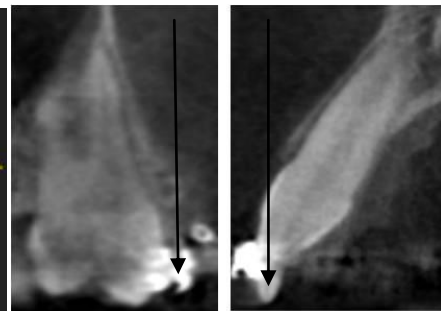
a: Axial view



b: coronal view



c: Mid sagittal view



d: Dental height at molar and incisor level

32.5° and the FHI (facial height index) of 58%. The



Figure 4(a-c): After placement of mini-implants and placing the active forces.

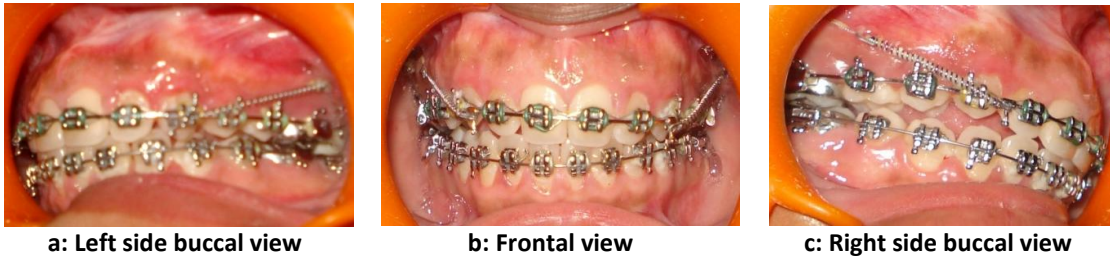
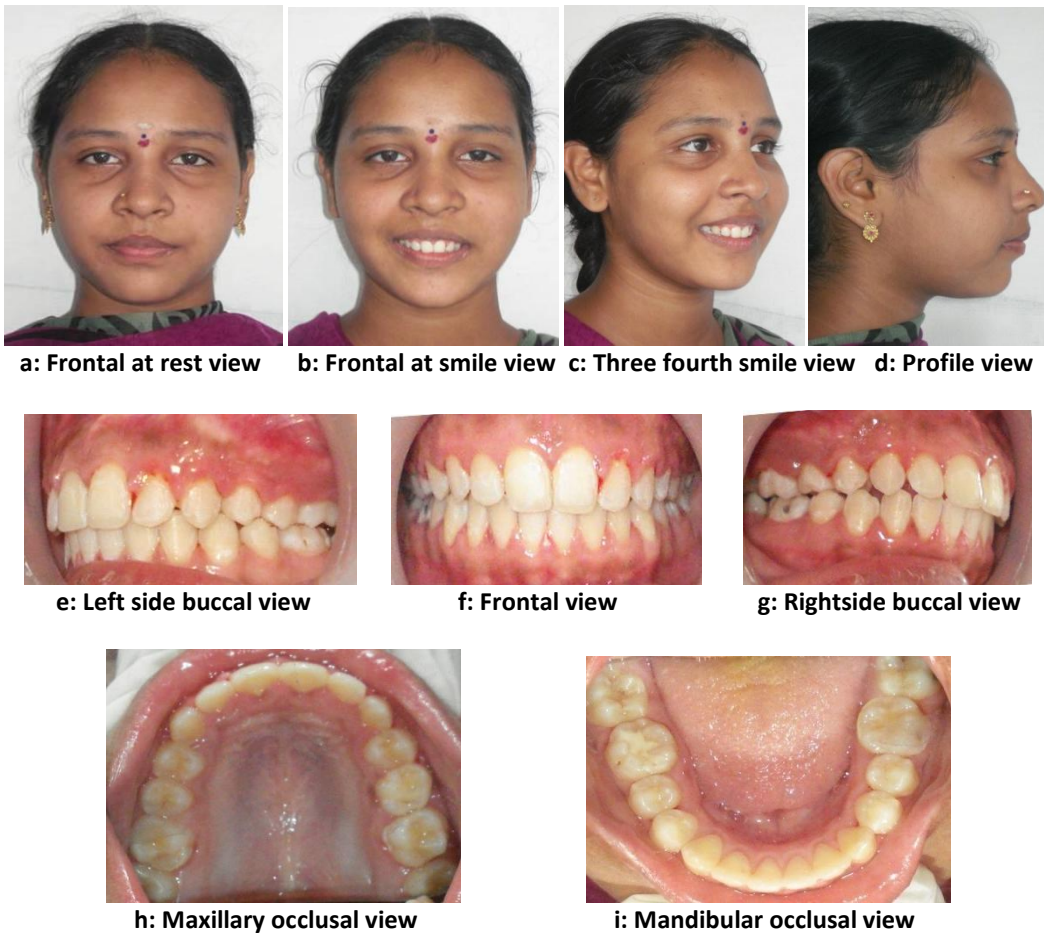


Figure 4(d-f): After completion of distalization and intrusion

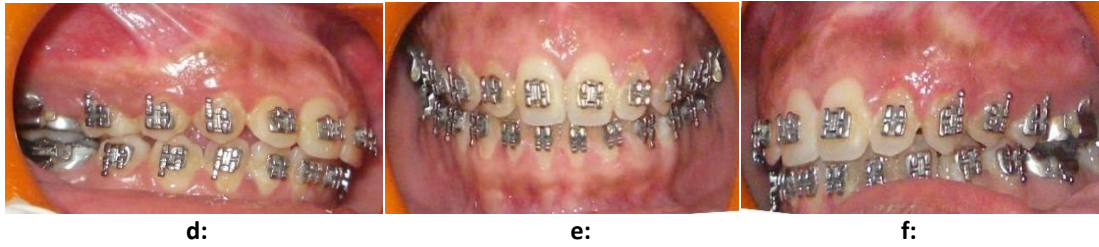

Figure 5 (a- i): Post treatment extraoral and intraoral photographs

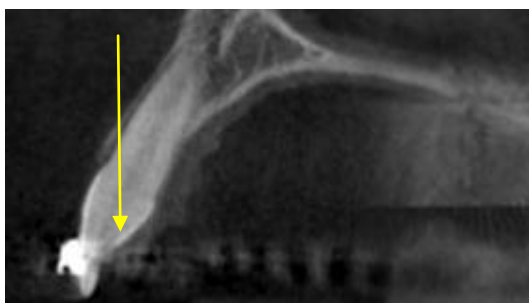


IMPA (incisor mandibular plane angle) of  $98.5^\circ$  reflected the proclination of lower incisors. The Z angle of  $65.6^\circ$  quantified the slight facial imbalance (Table 1). There were no significant

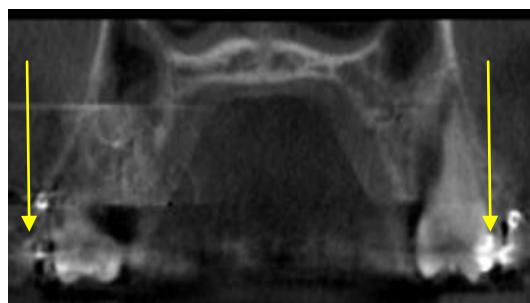
signs or symptoms of temporomandibular disorders.

#### TREATMENT OBJECTIVES

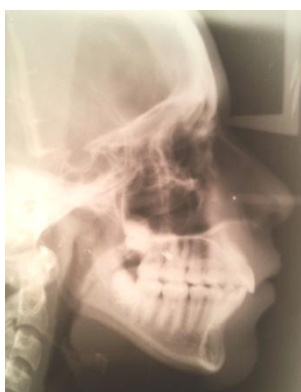**Figure 6 (a-d): Post treatment radiographs**



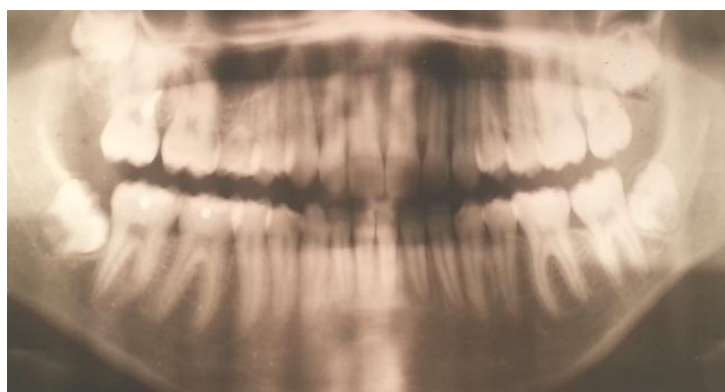
**a: CBCT image showing decrease in molar dental height**



**b: CBCT image showing decrease in incisor dental height**



**c: Cephalogram**



**d: Orthopantamogram**

The treatment objectives were to (1) align and level the teeth in both arches and establish a functional occlusion, (2) normalize the overjet and overbite (3) achieve class I molar and canine relationship (4) improve dental symmetry (5) obtain a balanced facial profile.

### TREATMENT ALTERNATIVES

The first alternative was retraction of the maxillary and mandibular anterior teeth using maximum anchorage following four first premolar extractions, and differential tooth movement to improve dental symmetry. To reduce the patient's lip protrusion and excess incisor exposure, this option would be unavoidable. The second alternative was using skeletal anchorage using MI to bring about the distalization along with intrusion of the upper arch dental segment. The patient preferred to have distalization without any forms of extraoral appliance. Therefore the use of intraoral distalization, supported by miniscrews placed bilaterally in the upper arch was planned to reduce the gumminess of the smile and provide an intrusive and distalization effect on the upper dental arch.

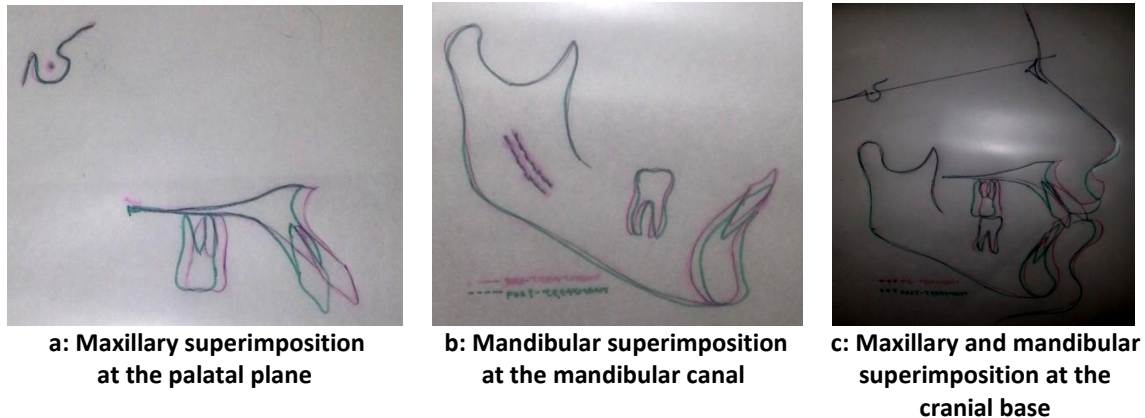
### TREATMENT PROGRESS

Both the upper and lower arches were levelled and aligned till it can passively take 0.019x0.025

inch rectangular stainless steel arch wires (Fig 2a-h). Mean while 13mm MI having 2mm diameter were placed bilaterally distal to the first molars as the interradicular bone was found to be sufficient in that place. The other reason for choosing this anatomic location was the presence of retained E in the upper arch on the right side resulted in close proximity between the roots of first molar and E (Fig 3a-d). Once the retraction wire was ready to be placed, it was given bull loops in it mesial to the canines so that the closed coil spring can be just ligated from the MI's head to the loop providing an intrusive and distalizing effect.

### TREATMENT RESULTS

Levelling and alignment was carried out in the upper and lower arches for 3 months after which MI were placed distal to the first molars in the upper arch on both the sides. After 2weeks of placing MI, the retraction force was applied using closed coil spring of 0.036 inches. To have maximum possible intrusion and retraction effect on the upper arch, the force vector was designed to pass above the center of resistance of the dentition, thereby reducing the gummy smile by rotating the occlusal plane upward anteriorly (Fig 4a-c). This phase lasted for almost 6 months to achieve both distalization and intrusion of the upper arch (Fig 4d-f). The treatment was

**Figure 7 (a-c): Cephalometric superimposition**

completed achieving class I molar and canine relation bilaterally and acceptable reduction in the gumminess of the smile. The overjet and overbite was also tried to be normalized to 2mm and 1mm respectively (Fig 5a-i). The maxillary first molars were distalized 3.5 to Class I molar relationship in 6 months (U6-VR distance). There was 2 mm intrusion of upper first molars (U6-SN) and 3mm intrusion of upper incisors (U1-MP) (fig6a,b) . Mandibular plane angle decreased 1° (SN -GoGn) during distalization and this change was still present at the completion of treatment. Sagittal skeletal positions were much improved with treatment (Fig 6c,d). Upper lip was reduced in its eversion and protrusion and the lower lip showed much improvement as the upper anterior teeth were retracted at the end of distalization (Fig 5d).

Cephalometric superimposition (SN plane at sella) showed maximum soft tissue changes such as approximation of both the lips to achieve proper lip seal which was again because of the maximum retraction and intrusion of the upper anteriors. The local maxillary superimposition (Anterior Nasal Spine-Posterior Nasal Spine plane at ANS) showed maximum retraction and intrusion of the upper incisors along with distalization of the first molar. The mandibular superimposition showed mild proclination and intrusion of lower incisors and resulting mild anchorage loss in the posterior region. (Figures 7a,b and c). Moderate expansion was also observed in upper first premolar, second premolar and first molar widths in the post treatment phase. (Fig 5h,i).

## DISCUSSION

The clinical efficacy<sup>18,19</sup> and stability<sup>20</sup> of temporary skeletal anchorage devices have been widely described. It is a very efficient method for solving orthodontic problems that cannot be corrected using conventional methods. Several

skeletal anchorage devices that are efficient in controlling anchorage have been developed to obtain anchorage control during the distalization movement. Using MI, distalization and retraction of the complete dental arch is possible without patient compliance. The vertical and horizontal component of force is determined by the vertical position of MI head. The maxillary posterior teeth appeared to have a tendency towards distal tipping with a slight intrusion, which was appropriate in this case. Therefore, the position of MI head should be considered carefully according to the type of malocclusion, and the amount and direction of tooth movement required. Sliding mechanics with the aid of the mini-implant anchorage and its application for the treatment of skeletal Class I and Class II malocclusions have been described previously.<sup>21</sup> Its application in nonextraction treatment, however, has not been widely discussed. The following case report highlights the use of mini-implants as an anchorage aid for distalization of maxillary molars. In this case the MI were implanted distal to the first molars by utilizing the presence of thick cortical bone and to provide a long range of force vector to have control on the tilt of occlusion plane which had to be tilted more upwards anteriorly to overcome the gummy smile which was the chief concern for the patient and the clinician.

## CONCLUSION

Successful distalization of maxillary molars was achieved in 6 months. The total treatment time was also optimum for this patient. The ease in placement and removal, the possibility of immediate loading and positive toleration by the patient are the main advantages of using MI.

Mini-implants use in this case has simplified the treatment plan and provided the absolute anchorage for the distal movement of buccal teeth

in a group as well as maximum retraction of the anterior teeth. In Class II bialveolar protrusion cases along with gummy smile which usually needs "Head gear treatment effect" i.e distalization and intrusion of the maxillary arch, therefore can be benefited by using mini-implants in the buccal sulcus for absolute anchorage and best results.

## REFERENCES

1. Kanomi R. Mini-implant for orthodontic anchorage. *J Clin Orthod.* 1997; 31:763–67.
2. Prabhu J, Cousley RR. Current products and practice: bone anchorage devices in orthodontics. *J Orthod.* 2006; 33:288–307.
3. Feldmann I, Bondemark L. Anchorage capacity of osseointegrated and conventional anchorage systems: a randomized controlled trial. *Am J Orthod Dentofacial Orthop.* 2008; 133:339.
4. Gray JB, Steen ME, King JG, Clark AE. Studies on the efficacy of implants as orthodontic anchorage. *Am J Orthod* 1983;83:311-7.
5. Byloff FK, Kärcher H, Clar E, Stoff F. An implant to eliminate anchorage loss during molar distalization: A case report involving the Graz implant-supported pendulum. *Int J Adult Orthodon Orthognath Surg* 2000;15:129-37.
6. Hilgers JJ. The pendulum appliance for Class II non-compliance therapy. *J Clin Orthod* 1992;26:706-14.
7. Joseph A, Butchart CJ. An evaluation of the pendulum distalizing appliance. *Semin Orthod* 2000;6:129-35.
8. Gianelly AA, Bednar J, Dietz VS. Japanese NiTi coils used to move molar distally. *Am J Orthod Dentofacial Orthop* 1991;99:564-6.
9. Gianelly AA, Vaitas AS, Thomas WM, Berger DG. Distalization of molars with repelling magnets. *J Clin Orthod* 1988;22:40-4.
10. Keles A, Sayinsu K. A new approach in maxillary molar distalization: Intraoral bodily molar distalizer. *Am J Orthod Dentofacial Orthop* 2000;117:39-48.
11. Giancotti A, Muzzi F, Greco M et al. Palatal implant supported distalizing devices: clinical application of the straumann orthosystem. *World Journal Orthod* 2002;3:135-139.
12. Oncağ G, Akyalçın S, Arıkan F. The effectiveness of a single osseointegrated implant combined with pendulum springs for molar distalization. *Am J Orthod Dentofacial Orthop.* 2007 Feb;131(2):277-84.
13. Sugawara J, Kanzaki R, Takahashi I, Nagasaka H, Nanda R. Distal movement of maxillary molars in nongrowing patients with the skeletal anchorage system. *Am J Orthod Dentofacial Orthop.* 2006 Jun;129(6):723-33.
14. Gelgör IE, Büyükyılmaz T, Karaman AI, Dolanmaz D, Kalayci A. Intraosseous screw supported upper molar distalization. *Angle Orthod.* 2004 Dec;74(6):838-50.
15. Escobar SA, Tellez PA, Moncada CA, Villegas CA, Latorre CM, Oberti G. Distalization of maxillary molars with the bone-supported pendulum: a clinical study. *Am J Orthod Dentofacial Orthop.* 2007 Apr;131(4):545-9.
16. Park HS, Lee SK, Kwon OW. Group distal movement of teeth using microscrew implant anchorage. *Angle Orthod.* 2005 Jul;75(4):510-7.
17. Chae JM. Unusual extraction treatment of Class I bialveolar protrusion using microimplant anchorage. *Angle Orthod.* 2007 Mar;77(2):367-76.
18. Chae JM. A new protocol of Tweed-Merrifield directional force technology with microimplant anchorage. *Am J Orthod Dentofacial Orthop.* 2006 Jul;130(1):100-9.
19. Park HS, Bae SM, Kyung HM, Sung JH. Micro-implant anchorage for treatment of skeletal Class I bialveolar protrusion. *J Clin Orthod.* 2001 Jul;35(7):417-22.
20. Miyawaki S, Koyama I, Inoue M, Mishima K, Sugahara T, Takano-Yamamoto T. Factors associated with the stability of titanium screws placed in the posterior region for orthodontic anchorage. *Am J Orthod Dentofacial Orthop.* 2003 Oct;124(4):373-8.
21. Chae J, Kim S. Running loop in unusual molar extraction treatment. *Am J Orthod Dentofacial Orthop* 2007 Oct;132(4):528-39.