

## COMBINATION OF PLATELET RICH FIBRIN MEMBRANE WITH DEMINERALIZED FREEZE-DRIED BONE ALLOGRAFT AND HYDROXYAPATITE GRAFT ALONG WITH BLEACHING IN MANAGEMENT OF DISCOLORED TOOTH WITH PERIAPICAL LESION

Mhatre Tanvi P.<sup>1\*</sup>, Vimala N.<sup>2</sup>, Mandke Lalitagauri P.<sup>2</sup>

<sup>1</sup>Department of Conservative Dentistry and Endodontics, D. Y. Patil University, School of Dentistry, Navi Mumbai.

<sup>2</sup>Department of Conservative Dentistry and Endodontics, D. Y. Patil University, School of Dentistry, Navi Mumbai.

### ABSTRACT

**Aim-** Rationale of surgical endodontics is to remove the diseased tissue present in the canal and around the apex, and retrofill the root canal space with biologically inert material so as to achieve a tight seal.

**Methods and Materials-** A periapical endodontic surgery was performed in the upper front teeth region. The surgical defect was filled with a combination of platelet rich fibrin membrane with demineralized freeze dried bone allograft and hydroxyapatite bone graft. Non-vital tooth bleaching procedure was carried after 3 months with hydrogen peroxide.

**Result-** Clinical examination revealed good wound healing. Radiologically graft material was replaced by bone formation at the end of 9 months.

**Conclusion-** On the basis of the results obtained in our case report, we hypothesize that use of PRF in conjunction with two different types of bone grafts might have induced the rapid rate of bone formation.

**Key words:** Platelet rich fibrin, bone graft, periapical lesion, bleaching.

### INTRODUCTION

Three to ten percentage of the endodontic practices are surgical treatments.<sup>1</sup>

Regenerative surgery includes use of barrier membrane and graft material to allow a regenerative and functional rehabilitation.<sup>2</sup>

Demineralized freeze-dried bone allograft (DFDBA) and hydroxyapatite bone graft (HA) have

been used to fill the periodontal infrabony defects.<sup>3</sup>

Plasma Rich Fibrin (PRF) represents new step in the platelet gel therapeutic concept.<sup>4</sup> It accelerates wound closure and mucosal healing.<sup>5</sup> This case report describes root canal therapy followed by apicectomy, filling the bony defect with PRF, DFDBA and HA. Non-vital tooth bleaching was carried out in the tooth with 9 months follow up.

### CASE REPORT

A 27 year-old male patient reported with complaint of discolored upper front tooth. History revealed trauma to the tooth ten years ago. On clinical examination, tooth 11 was discolored and

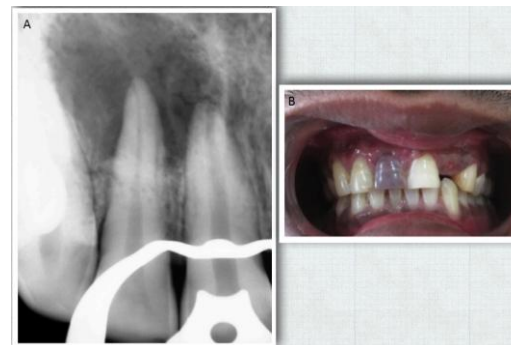

Fig. 1- Pre operative photograph and Pre-operative radiograph showing periapical lesion extending from 11 to mesial aspect of 12

pink in color. There was no mobility, swelling or pus exudation in relation to 11,12. Vitality test showed no response with 11 and 12 and a delayed response with 13. A periapical radiograph revealed

**\*Corresponding author:**

**Email: tanvi\_mhatre@yahoo.com**

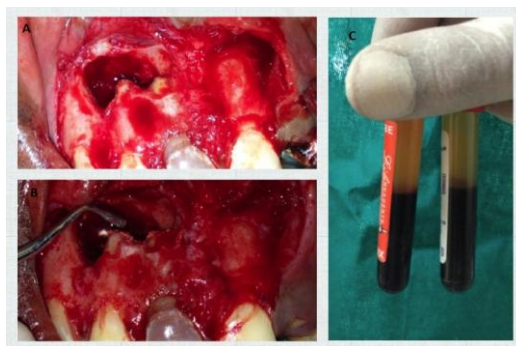presence of intrabony defects with tooth no. 11,12 and extending to the mesial side of 13. (12.2mm X 14.5mm corresponding to length and width of the lesion.) [Fig. 1]

It was decided to do root canal treatment in 11, 12, and 13 and remove the lesion surgically. Root canal treatment was performed using step back technique. The root canals were obturated by lateral condensation technique.

### Surgical procedure

Under local anesthesia full thickness mucoperiosteal flap was reflected by buccal sulcular incision from the distal of the tooth 21 to distal of 13. The loss of small portion of labial cortical plate was evident in relation with 11 and 12. Bony window was prepared to access the lesion using rotary, long shank straight surgical round bur.

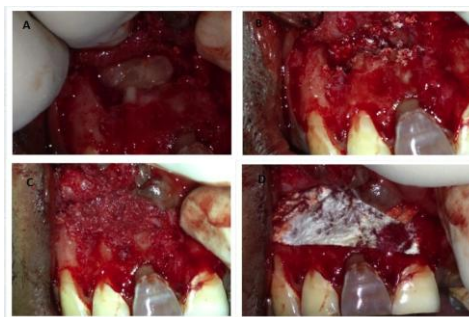
The lesion measured approximately 12mm X 14mm X 10mm corresponding to length, width and depth of the lesion. Tissue curettage was done followed by irrigation. Using no.702 tapered fissure bur root end resection of 3mm was performed in teeth 11 and 12. Glass Ionomer Cement (Type 2) was used as a root end filling material and placed in the apical cavity preparation. [Fig.2]



**Fig-2-Enucleation of periapical Cyst, Retrograde filling of 11 and 12 with Biodentine, PRF vials.**

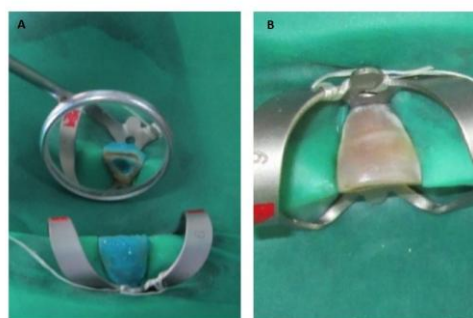
PRF preparation was done using standardize technique. DFDBA with size < 500u and Biphasic hydroxyapatite -β-tricalcium phosphate (HA + b TCP) with a particle size of 0.25-1mm were carried and both the materials were packed into the defect to the level of defect walls. Sterile collagen periodontal membrane was placed for the stabilization of material. Flap was repositioned and sutured. Periodontal pack was placed. [Fig.3]

Patient was given antibiotic, analgesic & anti-inflammatory coverage and 0.12% chlorhexidine



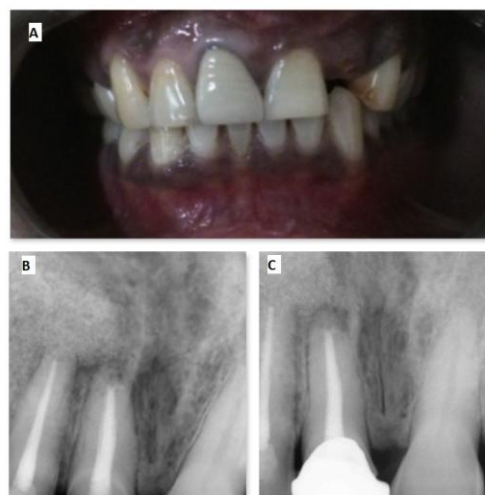
**Fig-3-PRF membrane, FDDB graft, OSSIFY bone graft, GTR membrane placement.jpg**

mouthwash for two weeks. The sutures were removed after one week. At three months a non-vital tooth bleaching procedure was conducted with Pola-Office as bleaching agent with 35% hydrogen peroxide. Bleaching was repeated after seven days. [Fig. 4] A permanent restoration was placed. Patient was given porcelain fused to metal



**Fig-4-Bleaching- Preoperative and Postoperative Photographs**

crown and was recalled after three months. [Fig. 5] Tooth 11, 13 did not require any coronal coverage; the access cavities were filled with light cured composite resin restoration.



**Fig-5-Esthetic crown in 11, 3months follow up, 9 months follow up.**

Follow up visits included clinical examination and evaluation of healing of periapical lesion radiographically. Patient remained asymptomatic.

## DISCUSSION

The present case report evaluated the clinical efficacy of PRF and DFDBA and HA + b TCP (Regenerative Bone Matrix) in treatment of intrabony defect. Biologically a blood clot is better space filler than all bone-grafting materials. A blood clot is the host's own biologic product, therefore chances of infectious disease transmission is rare.<sup>2</sup> It is indispensable in tissue wound healing.<sup>5</sup> Bone grafts alone without blood clot or angiogenic factors are unlikely to be capable of promoting periapical wound healing.<sup>5</sup> PRF acts like a fibrin bandage.<sup>2</sup> PRF is a rich source of PDGF, TGF, IGF etc. and are believed to play a major role in bone metabolism and potential regulation of cell proliferation. PDGF promotes the strength of healed tissue. TGF-B activates fibroblasts to form procollagen which deposits collagen within the wound. PRF facilitates healing by controlling the local inflammatory response.<sup>2</sup> It shows several advantages over PRP. The combination of bone grafts and growth factors in PRF may be suitable to enhance bone density.<sup>6</sup> A combination of PRF with DFDBA demonstrated better results in probing depth reduction and clinical attachment level gain as compared to DFDBA alone in the treatment of intrabony defects.<sup>7</sup> HA has shown positive results with respect to periodontal regeneration in periapical defects.<sup>5</sup> (HA + b TCP) bone graft appears to be a beneficial material in treatment of such defects.<sup>8</sup> HA used with DFDBA has a synergistic effect of osteoinduction. Bone formation occurred as early as four weeks in combination of DFDBA and HA.<sup>3</sup> GTR covers the bone and periodontal ligament by separating them from the gingival epithelium. This prevents epithelium migration into the wound. It favors repopulation of the area by cells from the periodontal ligament & bone.<sup>9</sup> It is concluded that GIC can be used as an apical sealant after root-end resection and provides good long-term clinical results.<sup>1</sup>

However, even after two cycles of bleaching (extra-coronal & intra-coronal) there was no improvement in the shade of tooth 11. Decision was made to prepare the tooth for 'porcelain fused to metal' crown in 11, due to economic status of the patient.

## CONCLUSION

From the presented case, it can be concluded that PRF and bone grafts are used in the

regeneration of tissue in a large periapical bony defect. The use of GTR might have accelerated the healing process; and enabled to achieve a healthy bone deposition. The goal of restoring the esthetics of patient was achieved using an aesthetic crown. [The permission for reporting the findings was duly obtained.]

## REFERENCES

1. Kenneth M. Hargreaves, Stephen Cohen, Louis H. Berman. Cohen's Pathways of the pulp. 10<sup>th</sup> edition. St Louis: Mosby. Elsevier Publication. 2011.
2. Paromita Mazumdar, Debabrata Nag, Sanjib Bhunia. Case Report- Treatment of periapical Lesion with Platelet Rich Fibrin. Indian Medical Gazette; January 2013; 28-33.
3. Sonal Mishra, R. K. Singh, Shadab, Mohammad, R. Pradhan, U. S. Pal. A Comparative Evaluation of Decalcified Freeze Dried Bone Allograft, Hydroxyapatite and Their Combination in Osseous Defects of the Jaws. J. Maxillofac. Oral Surg 2010; 9(3): 236-240.
4. David M. Dohan, Joseph Choukroun, Antoine Diss, Steve L. Dohan, Anthony J. J. Dohan, Jaafar Mouhyi, Bruno Gogly. Platelet-rich fibrin (PRF): A second-generation platelet concentrate. Part III: Leucocyte activation: A new feature for platelet concentrates? Oral Surg Oral Med Oral Pathol Oral Radiol Endod 2006; 101:E51-5.
5. Vasundara Yayathi Shivashankar, Dexton Antony Johns, Vidyanath S, George Sam. Case Report-Combination of platelet rich fibrin, hydroxyapatite and PRF membrane in the management of large inflammatory periapical lesion. Journal of Conservative Dentistry 2013; 16:261-264.
6. Sunitha Raja V, Munirathnam Naidu E. Platelet-rich fibrin: Evolution of a second-generation platelet concentrate. Indian J Dent Res. 2008; 19(1).
7. Chhaya Bansal, Vipin Bharti. Evaluation of efficacy of autologous platelet-rich fibrin with demineralized-freeze dried bone allograft in the treatment of periodontal intrabony defects. J Indian Soc Periodontol. 2013;(3): 361-366.
8. Bharadwaj T Kaushick, Jayakumar ND, Padmalatha O, Sheeja Varghese. Treatment of

human periodontal infrabony defects with hydroxyapatite + b tricalcium phosphate bone graft alone and in combination with platelet rich plasma: A randomized clinical trial. Indian Journal of Dental Research. 2011; 22(4).

9. Michael G. Newman, Henry H. Takej, Perry R. Klokkevoid, Fermin A. Carranza. Carranza's Clinical Periodontology.10<sup>th</sup> Edition. St Louis: Saunders. Elsevier. 2007.